

Baseline Screening Protocol, results and workup recommendations

Negative: No nodules, **RETURN FOR ANNUAL REPEAT** **IELCAP = 1**

Semi-Positive: RETURN FOR ANNUAL REPEAT **IELCAP = 2**

- a. Only nonsolid nodules, regardless of size, or
- b. Largest solid, part-solid (solid component) < 6.0 mm,
- c. Peri-fissural nodules < 10.0 mm in diameter with smooth margin and lentiform, oval, or triangular shape;
- d. Costal-, mediastinal- and diaphragmatic-pleural nodules < 10.0 mm in diameter with smooth margin and lenticular, oval, semi-circular, triangular shape.
- e. **Indeterminate:** **IELCAP = 3**
 Largest solid, part-solid (solid component) 6.0-14.9 mm. **RETURN FOR FOLLOW-UP LDCT 3 MONTHS after baseline, and if nodule shows a) decrease, b) no growth, or c) growth at a nonmalignant rate, then RETURN IN 9 MONTHS FOR FIRST ANNUAL REPEAT SCREENING.** **IELCAP = 2**

Positive: **IELCAP = 4**

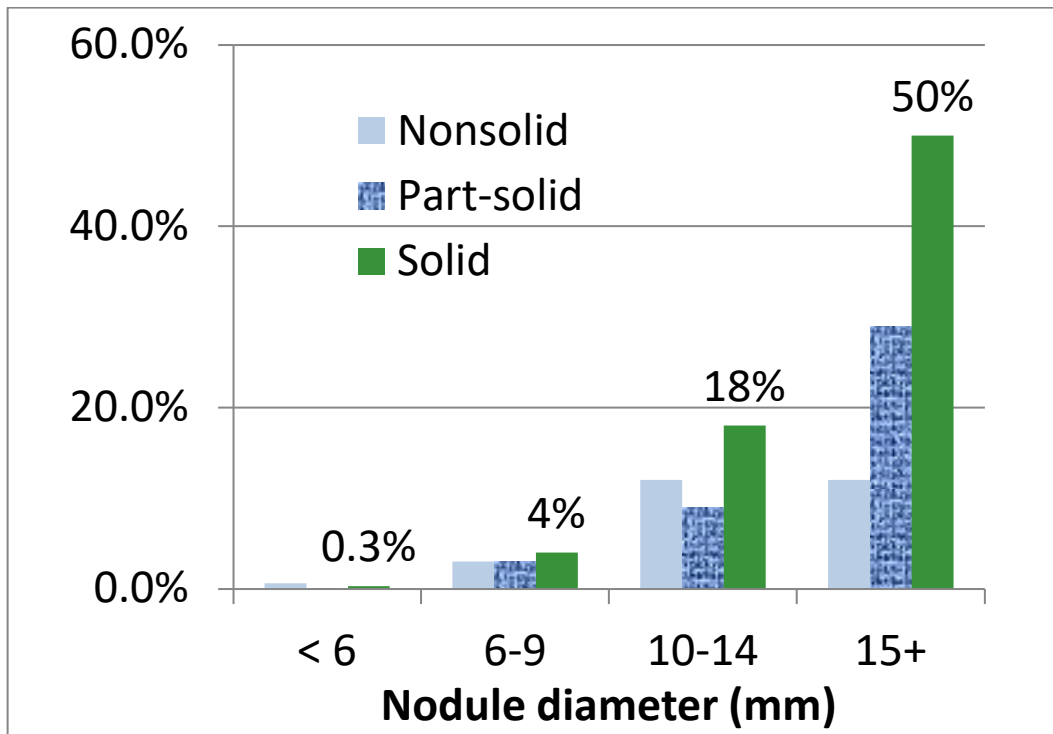
- a. Largest solid, part-solid (solid component) 6.0-14.9 mm *after a follow-up CT scan in 3 months shows growth at a malignant rate;*
- b. Largest solid or part-solid nodule 15.0 mm or larger;
- c. Solid endobronchial nodule.

WORKUP OPTIONS FOR POSITIVE RESULTS:

- A. If the nodule appearance is highly suggestive of lung cancer, immediate biopsy is recommended.
- B. Another option for nodules > 10mm is to perform PET scan. If the PET result is positive, biopsy is recommended, but, if negative or indeterminate, a low-dose CT 3 months later is performed. If, growth is documented on that CT, biopsy is recommended. If there is partial or complete resolution on CT, further workup stops and return for first annual repeat screening. **IELCAP=2.**
- C. When multiple nodules are present and occult infection or inflammation is a possibility, an added option is a course of a broad spectrum antibiotic with anaerobic coverage followed by low-dose CT 1-3 months later (77). If there is further growth, biopsy is recommended. If there is partial or complete resolution on CT, return for first annual repeat screening. **IELCAP=2.**
- D. If an endobronchial nodule is identified at the time of the initial CT, the participant is asked to cough vigorously several times and the region of interest is reimaged at that time. If the endobronchial nodule is not recognized at the time of the baseline CT scan, the participant is recalled for a follow-up low-dose CT within one month. At the time of the follow-up CT scan, the participant is asked to cough vigorously several times. If the nodule is still present, the participant is referred for pulmonary consultation, and if necessary, bronchoscopy. If classic features of retained secretions are identified such as low attenuation, air bubbles, stranding and multiplicity, call back is not necessary [also see NCCN Guidelines 2016 (97)].

NOTE: All participants in whom diagnostic work-up was stopped or the biopsy, if adequate, did not lead to a diagnosis of lung cancer, **REPEAT CT 12 months is to be performed.**

Baseline Round. Probability of malignancy based on nodule size and consistency



Baseline Round: Change needed in nodule diameter to identify growth at a malignant rate for volume doubling times of 180 days or faster

BASELINE ROUND		
Original diameter (mm)	Diameter (mm) in 3 months without measurement error VDT: 180 days	Diameter (mm) in 3 months with measurement error VDT: 180 days
6.0	6.7	7.1
7.0	7.9	8.3
8.0	9.0	9.4
9.0	10.1	10.5
10.0	11.2	11.6
11.0	12.3	12.7
12.0	13.5	13.9
13.0	14.6	15.0
14.0	15.7	16.1